

Mid-calf level as a puncture site is not safe enough for thermal ablation of the small saphenous vein

SAGE Open Medicine

Volume 5: 1–4

© The Author(s) 2017

Reprints and permissions:

sagepub.co.uk/journalsPermissions.nav

DOI: 10.1177/2050312117731474

journals.sagepub.com/home/smo

Soner Sanioglu¹, Halit Yerebakan¹, Ali Ozgen², Huseyin O Ozdemir², Nurcan K Sancar³ and Mustafa B Farsak¹

Abstract

Background: Endovenous thermal ablation of the small saphenous vein carries a risk for sural nerve injury. Ablation above mid-calf level is recommended to avoid it. However, this strategy could not eradicate this complication. We present our results of consecutive 30 small saphenous vein thermal ablations which are performed after ultrasonographic identification of the sural nerve.

Methods: We studied 26 consecutive subjects with a total of 30 limbs. Ablation was performed proximal to the risk point by a 1470-nm diode laser. Patients were asked to attend follow-up outpatient controls at 7 days, 30 days, and 180 days postoperatively. Rate of identification of the sural nerve by ultrasonography, safety of the mid-calf level as a puncture site and postoperative sural nerve damage were assessed.

Results: The sural nerve identification was achieved by ultrasonography in all patients except for one. Mid-calf level as a puncture site was not safe in three (10%) extremities. None of the patients showed any evidence suggesting postoperative sural nerve damage.

Conclusion: Choosing the puncture site according to the risk point may be more reasonable than general mid-calf level which is being used.

Keywords

Small saphenous vein ablation, SSV-sural nerve relationship, sural nerve ultrasound, nerve lesions

Date received: 8 July 2017; accepted: 22 August 2017

Introduction

Varicose veins are caused by incompetence of the small saphenous vein (SSV) with an incidence rate of 15% in all patients.¹ Although not supported by the extensive randomized studies, endovenous thermal ablation method is found to be superior to surgery due to minimally invasive approach and better results.² The ideal access point for endovenous thermal ablation has found to be the most distal segment of the vein where reflux continues.³ However, the ablation of distal segment of SSV carries higher risk due to the anatomical proximity of the sural nerve.⁴ The latest European guidelines recommend access to the SSV to be gained no lower than mid-calf level.⁵ Nevertheless, puncturing the vein at mid-calf level would decrease the rate of sural nerve injury but could not eradicate it.^{3,6}

Although several anatomical variations are documented, the sural nerve usually forms as a result of merging two cutaneous branches located laterally and medially. After

merging, it enters into saphenous compartment and descends through the ankle where it close contacts with SSV. The starting point of close contact is referred to as the 'risk point'.⁷ The sural nerve injury during SSV treatments is more probable distally from this point. The risk point is mostly found at distal mid-calf region. But in some individuals, it could be located in the proximal mid-calf region.⁸ For

¹Department of Cardiovascular Surgery, Yeditepe University Hospital, Istanbul, Turkey

²Department of Radiology, Yeditepe University Hospital, Istanbul, Turkey

³Department of Anesthesiology and Reanimation, Yeditepe University Hospital, Istanbul, Turkey

Corresponding author:

Soner Sanioglu, Fenerbahçe mah. Fenerli Reis sok., No:5/2 34726 Kadıköy, İstanbul, Turkey.

Email: sanioglu@gmail.com



Creative Commons Non Commercial CC BY-NC: This article is distributed under the terms of the Creative Commons

Attribution-NonCommercial 4.0 License (<http://www.creativecommons.org/licenses/by-nc/4.0/>) which permits non-commercial use, reproduction and distribution of the work without further permission provided the original work is attributed as specified on the SAGE and Open Access pages (<https://us.sagepub.com/en-us/nam/open-access-at-sage>).

this reason, ideal puncture site to prevent sural nerve injury should be proximal to the risk point instead of the generally used mid-calf level.

It has been shown that the risk points can be determined by ultrasonography (USG).⁸ The aim of this study was to investigate the results of ultrasound identification of the risk point prior to thermal ablation of the SSV.

Materials and methods

Patient population

This study included 26 consecutive subjects with a total of 30 limbs who underwent endovenous thermal ablation due to incompetence of SSV between May 2013 and February 2017 at our institution. Thermal ablation was not attempted in patients who had varicose veins secondary to deep vein thrombosis, had peripheral arterial diseases (ankle/brachial index < 0.8), were pregnant or nursing women, and immobile patients. This study met all guidelines and was approved by the institutional review board. An informed consent was filled for each individual patient who enrolled in the study. Patients were evaluated by Clinical, Etiologic, Anatomic and Pathologic (CEAP)⁹ classification and Venous Clinical Severity Score (VCSS)¹⁰ pre- and postoperatively and the data were recorded in the database.

Ultrasonographic detection of the risk point

Ultrasonographic inspections were performed by using IU22 USG device (Philips, The Netherlands) with a 5–17 MHz multifrequency linear probe. The sural nerve was identified using the method defined by Ricci et al.⁸ Besides utilizing standard grey scale evaluation for the detection of the sural nerve, colour Doppler functions were used in transverse sections of saphenous compartment in the distal half of the calf. Small saphenous vein and sural nerve could easily be distinguished from each other by encoding colour in the vessel during assessment. In addition, the transducer was moved up and down to benefit from anisotropic artefacts of structures (muscle, tendon, etc.) apart from the nerves. The sural nerve usually appears as a round/ovoid structure with 1–2 mm diameter, moderately echogenic, containing ‘black spots’ corresponding to nerve (Figure 1). Once the sural nerve was identified, it was followed throughout the course of SSV towards the proximal end and the risk point was tried to be determined. The risk point was accepted to be the point where the sural nerve exits saphenous compartment and becomes 5 mm apart from the SSV (Figures 2 and 3).

Ablation procedure

The SSV was cannulated percutaneously using a 16-gauge needle with the aid of USG. We assured that the cannulation was done proximal to the risk point. A 6F introducer sheath (INPUT Introducer sheath, Medtronic Ireland Parkmore

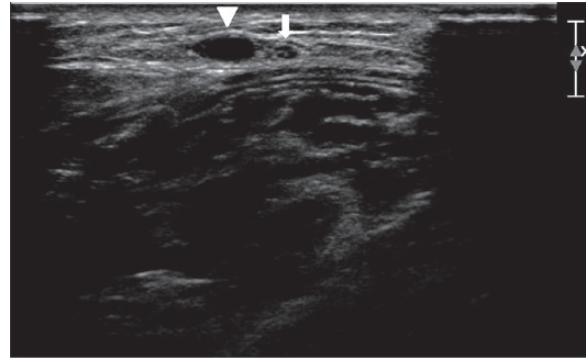


Figure 1. Ultrasonographic view of the sural nerve. The nerve appears a round/ovoid structure (arrow) and containing ‘black spots’ corresponding to nerve fibres, surrounded by an echogenic sheath (perineurium). The nerve is located in the saphenous compartment and next to the small saphenous vein (arrow head).

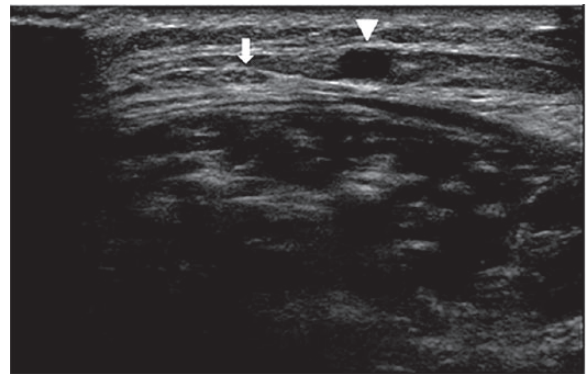


Figure 2. Ultrasonographic detection of the risk point: Sural nerve (arrow) is out of the saphenous compartment and 5 mm away from the small saphenous vein (arrow head).

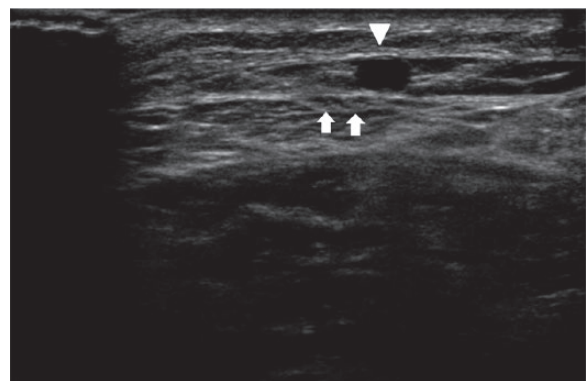


Figure 3. Ultrasonographic detection of the risk point: Sural nerve is divided into two cutaneous branches (arrows) and out of the saphenous compartment but cutaneous nerves are not 5 mm away from the small saphenous vein (arrow head).

Business Park West, Galway, Ireland) was inserted to SSV over a guide wire which was placed through the needle used in cannulation. A radial laser probe (ELVeS Radial, Biolitec

AG, Bonn, Germany) was inserted into the vein through this sheath and advanced until 2 cm below the saphenopopliteal junction by guidance of USG. Following infiltration of perivenous field with tumescent anaesthesia (500 mL saline 0.9%, 50 mg marcaine 0.5%, 0.5 mL epinephrine 1:1000, 50 mEq NaHCO₃) ablation was performed at linear endovenous energy density of 50 J/cm by a 1470-nm diode laser. The length of ablated segment was recorded. Before finishing the procedure, closure of SSV and patency of popliteal vein was controlled by Doppler USG. Cutaneous varicose veins were excised in the same operating session using mini phlebectomy method. The procedure was finalized following compression bandaging of the leg.

Follow-up protocol

Patients were asked to attend follow-up outpatient at 7 days, 30 days, and 180 days postoperatively. During follow-up examinations, postoperative sural nerve damage was assessed by numbness, and hypo-aesthesia or anaesthesia of the skin at posterolateral surface of the leg, and lateral border of the foot. Radiating pain to the forefoot with constant burning and painful paraesthesia or hypersensitivity, which may have been caused by neuromas following a nerve damage, were questioned during every postoperative follow-up visit. Complications and duration of symptoms were recorded. CEAP class and VCSS were calculated and recorded at first- and sixth-month follow-up appointments.

Statistical analysis

Descriptive statistics were used to specify patient characteristics. Categorical data were represented by frequency distributions and percentages, whereas continuous variables were expressed as mean \pm standard deviation. Univariate analysis of continuous variables was performed using student *t* tests, and categorical variables were compared using chi-square test of homogeneity and independence in contingency tables. All *p* values were two-sided and a *p* < 0.05 was accepted to be significant. Data were analyzed using IBM SPSS Statistics 21.0 (IBM Corp., Armonk, NY, USA).

Results

The risk point was determined by USG in all patients except for one because of excessive fatty tissue under the skin (*n* = 25, 96%). Ablation was performed proximal to the risk point in these patients (25 patients with 29 extremities). The ablation in the patient without a determined risk point (*n* = 1, 4%) was performed in proximal mid-calf region. The risk point was detected above mid-calf level in three (10%) extremities. The mean age of the patients was 52 \pm 10 years and 35% (*n* = 9) were male. Baseline characteristics showed that only three patients had hypertension and three patients had type 2 diabetes mellitus. No additional comorbidities

were recorded. According to CEAP classification, majority of the patients were in C₂-C₃ stage. One patient was C₄ and none of the patients were with stage C₅-C₆.

Preoperative mean VCSS is 4 \pm 1.3. Mean preoperative SSV diameter of patients was 6.3 \pm 1.1 mm, and the mean vein segment length of applied ablation was 16.3 \pm 3.5 cm. Four patients received bilateral endovenous thermal ablation to SSV. In addition, ablation of the great saphenous vein was performed in six patients. Minimally invasive phlebectomy in the same operating session was performed in every patient. None of the patients in the study showed any evidence suggesting postoperative sural nerve damage.

Postoperative deep vein thrombosis or other major complications were not observed in any patient. All patients, excluding one patient in whom recanalization was determined, showed significantly decreased CEAP clinical stage and VCSS. First-month and sixth-month mean VCSS is 0.5 \pm 0.9 and 0.5 \pm 1, respectively.

Discussion

A recent meta-analysis that analyzed 49 studies has shown that the rate of neurologic damage during thermal ablation of SSV is 5%–10%.¹¹ Considering individual differences, it is not unexpected to see sural nerve damage following endovenous thermal ablation procedures that are performed without any examination of the relationship between these two structures. In another recent meta-analysis, evaluating 3974 extremities and scanning for merging zone of the two cutaneous nerve branches forming sural nerve, the merging zone was found to be in the upper half of the calf in 16%.¹² The risk point is very close the merging zone. For this reason, this meta-analysis indicates indirectly that the risk point could be located in the upper half of the calf in some individuals. In addition, other published series, examining the relationship between saphenous vein and sural nerve, confirmed that the risk point would be located at proximal half of the calf.⁸ We have found that the risk point was above mid-calf level in three (10%) extremities out of the total 29 examined. General approach could result in sural nerve injury in those patients.

Ricci has defined the contact point of SSV and sural nerve as the risk point.⁷ In this study, the risk point was accepted to be the point where sural nerve exits the saphenous compartment and becomes 5 mm apart from the SSV. Variations in our definition made it difficult to compare the results from our study with others addressing the risk point. However, potential thermal damage in perivenous area during endovenous thermal ablation procedures urged us to differentiate. There are no clear or safe distances defined in the literature regarding how to avoid thermal damage in perivenous structures. Therefore, previous defined distance criteria for skin were used to determine the risk point.^{13,14} In addition, tumescent infiltration could decrease the safe distances between two structures if sural nerve is still in saphenous

compartment. For this reason, exit point of the sural nerve from saphenous vein compartment was accepted as another criterion. The absence of sural nerve damage in all of the patients shows that our identification is highly reliable. However, larger studies are needed to draw definitive conclusions.

The literature examining the relationship between sural nerve and saphenous vein ultrasonographically is scarce. Ricci et al. reported that skin changes due to chronic venous incompetence can disrupt ultrasonographic viewing of the sural nerve.⁸ Depending on these data, absence of patients with stage C₅-C₆ can be a limitation of this study. It is not clear whether or not ultrasonographic detection of the risk point is reliable in patients with advanced-stage chronic venous incompetence. In our study, the risk point was detected by USG in all extremities except one limb. Failure to localize the risk point in the patient with morbid obesity is linked to an increased presence of fatty tissue under the skin.

Limitation of the study

The number of patients included in the study is limited. Small saphenous vein incompetence is responsible for 15% of the varicose veins. Approximately 100 endovenous ablation procedure is performed per year at our institution. SSV ablation is performed less frequently compared with the great saphenous ablation. During 4 years, only 30 patients could be included in the study. Another limitation is absence of a control group. We avoided to set up control group due to our belief that ablation below the risk point might result in permanent nerve injury.

Conclusions

As a result, risk points can be detected by USG in the majority of patients and it could be located in the upper half of the calf. Choosing the puncture site according to risk point may be more reasonable than general approach to prevent sural nerve injury. Further studies are needed to have a final conclusion. Until the results of nonthermal ablation are clear, this issue should not be ignored.

Declaration of conflicting interests

The author(s) declared no potential conflicts of interest with respect to the research, authorship, and/or publication of this article.

Ethics approval

Ethical approval for this study was obtained from Yeditepe University ethics committee of clinical investigation (approval number/ID: 388/07.01.2013).

Funding

The author(s) received no financial support for the research, authorship, and/or publication of this article.

Informed consent

Written informed consent was obtained from all subjects before the study.

References

1. Tellings SS, Ceulen RP and Sommer A. Surgery and endovenous techniques for the treatment of small saphenous varicose veins: a review of the literature. *Phlebology* 2011; 26(5): 179–184.
2. Samuel N, Carradice D, Wallace T, et al. Randomized clinical trial of endovenous laser ablation versus conventional surgery for small saphenous varicose veins. *Ann Surg* 2013; 257(3): 419–426.
3. Samuel N, Wallace T, Carradice D, et al. Endovenous laser ablation in the treatment of small saphenous varicose veins: does site of access influence early outcomes? *Vasc Endovascular Surg* 2012; 46(4): 310–314.
4. Kerver AL, van der Ham AC, Theeuwes HP, et al. The surgical anatomy of the small saphenous vein and adjacent nerves in relation to endovenous thermal ablation. *J Vasc Surg* 2012; 56(1): 181–188.
5. Wittens C, Davies AH, Bækgaard N, et al. Management of chronic venous disease: clinical practice guidelines of the European Society for Vascular Surgery (ESVS). *Eur J Vasc Endovasc Surg* 2015; 49(6): 678–737.
6. Doganci S, Yildirim V and Demirkilic U. Does puncture site affect the rate of nerve injuries following endovenous laser ablation of the small saphenous veins? *Eur J Vasc Endovasc Surg* 2011; 41(3): 400–405.
7. Ricci S. Anatomy. In: Goldman MP, Guex JJ and Weiss RA (eds) *Sclerotherapy: treatment of varicose and telangiectatic leg veins*. Edinburgh, Saunders Elsevier, 2011, pp. 1–24.
8. Ricci S, Moro L and Antonelli Incalzi R. Ultrasound imaging of the sural nerve: ultrasound anatomy and rationale for investigation. *Eur J Vasc Endovasc Surg* 2010; 39(5): 636–641.
9. Reporting standards in venous disease. Prepared by the Subcommittee on Reporting Standards in Venous Disease, Ad Hoc Committee on Reporting Standards, Society for Vascular Surgery/North American Chapter, International Society for Cardiovascular Surgery. *J Vasc Surg* 1988; 8(2): 172–181.
10. Rutherford RB, Padberg FT Jr, Comerota AJ, et al. Venous severity scoring: an adjunct to venous outcome assessment. *J Vasc Surg* 2000; 31(6): 1307–1312.
11. Boersma D, Kornmann VN, van Eekeren RR, et al. Treatment modalities for small saphenous vein insufficiency: systematic review and meta-analysis. *J Endovasc Ther* 2016; 23(1): 199–211.
12. Ramakrishnan PK, Henry BM, Vikse J, et al. Anatomical variations of the formation and course of the sural nerve: a systematic review and meta-analysis. *Ann Anat* 2015; 202: 36–44.
13. Galanopoulos G1 and Lambidis C. Minimally invasive treatment of varicose veins: endovenous laser ablation (EVLA). *Int J Surg* 2012; 10(3): 134–139.
14. Joh JH, Kim WS, Jung IM, et al. Consensus for the treatment of varicose vein with radiofrequency ablation. *Vasc Specialist Int* 2014; 30(4): 105–112.